Sensorimotor Returning in Complex Regional Pain Syndrome Parallels Pain Reduction

Burkhard Pleger, MD,[1] Martin Tegenthoff, MD,[1] Patrick Ragert,[2,3] Ann-Freya Förster, MD,[4] Hubert R. Dinse, PhD,[2] Peter Schwenkreis, MD,[1] Volkmar Nicolas, MD,[4] and Christoph Maier, MD[5]

Patients with complex regional pain syndrome (CRPS) and intractable pain showed a shrinkage of cortical maps on primary (SI) and secondary somatosensory cortex (SII) contralateral to the affected limb. This was paralleled by an impairment of the two-point discrimination thresholds. Behavioral treatment over 1 to 6 months consisting of graded sensorimotor retuning led to a persistent decrease in pain intensity, which was accompanied by a restoration of the impaired tactile discrimination and regaining of cortical map size in contralateral SI and SII. This suggests that the reversal of tactile impairment and cortical reorganization in CRPS is associated with a decrease in pain.

Ann Neurol 2005;57:425–429

Complex regional pain syndrome (CRPS) is a serious complication that occurs with (type II) or without (type I) apparent peripheral nerve lesion after an often disproportionate trauma of a limb.[1,2] Several theories proposed the existence of pathophysiological mechanisms of central origin.[3–8] Recent findings provide evidence for a shrinkage of cortical maps on primary somatosensory cortex (SI) contralateral to the CRPS affected limb.[3,6,7] The degree of reduction thereby appeared to be linked to pain intensity.[6,7]

In this study, we sought to determine whether behavioral treatment implicating the reinforcement of sensory feedback mechanisms may alter cortical reorganization and also pain perception. In six patients with intractable pain due to CRPS type I of one upper limb, drug therapy was accompanied by a pain adapted sensorimotor training program consisting of graded desensitization protocols and motor tasks in ascending difficulty. To assess possible alterations of cortical maps in SI and SII (primary and secondary somatosensory cortex) (Table 1), patients were subjected to functional magnetic resonance imaging (fMRI) during electrical stimulation of the index finger (IF) before and after therapy. We combined each fMRI session with measurements of the two-point discrimination thresholds on the tip of the IF to assess therapy-induced changes in tactile perception.

Patients and Methods

Informed consent was obtained from all patients, and the study was approved by the local ethics committee. All patients first underwent electroneurographic and clinical neurological examination to exclude a peripheral nerve injury (CRPS type II) as another possible origin of cortical reorganization.[9] Patients with cutaneous damage and edema of the CRPS affected IF were excluded to avoid erroneous high-stimulation intensities during fMRI because of peripheral disturbances. Only patients in whom signs of CRPS affected the whole hand including all digits were recruited. In all patients, we found an increased bone metabolism of the affected hand as shown by three-phase scintigraphy.[10] All patients fulfilled the revised criteria of CRPS I (clinical signs of patients as listed in Table 2: hyperalgesia: Patients 1–6; allodynia: Patients 1 and 6; skin color changes: Patients 1–6, sweating changes: Patients 2, 5; tremor: Patient 5; dystonia: none; trophic changes: Patients 1–6, temperature asymmetry: Patients 1, 4, 5).[2] Before each measurement, patients estimated their pain intensity experienced during the last 4 weeks as well as the pain intensity felt directly before the fMRI session on a numeric rating scale (NRS: ranging from 0 = no pain to 10 = most extreme pain). In addition, the patients rated the degree of immobility (mean degree during last 4 weeks as well as actual degree) in percentages (100 = no immobility, 0 = complete immobility).

Pain-adapted sensorimotor treatment protocols were applied to the patients 3 to 4 days a week and in two to three sessions lasting at least 15 to 30 minutes over a period ranging from 1 to 6 months. Drug therapy was not changed during this period (celecoxib 400mg daily: Patients 1, 3–5; valdecoxib 40mg daily: Patient 6; gabapentin 1,800mg daily: Patients 2, 5, 6).

fMRI measurements were performed with a whole-body 1.5 T scanner (Magnetom Symphony, Siemens Medical Systems, Germany) equipped with a high-power gradient system (30mT/m/sec; SR 125T/m/sec). We acquired blood oxygen level dependent (BOLD) sensitive images with a single-shot spin-echo echo planar imaging sequence (TR, 1,600 milliseconds; TE, 60 milliseconds; matrix, 64 × 64; field of view, 224mm; 5mm slice thickness; 1mm gap between slices, voxel 3.5 × 3.5 × 5mm). Sixteen transaxial slices that covered the whole brain excluding cerebellum were adjusted according to the anterior commissure–posterior commissure connection. Each fMRI session consisted of nine blocks of rest and eight blocks of stimulation, each of which contained 40 scans.

From the [1]Department of Neurology, BG-Kliniken Bergmannsheil; [2]Institute for Neuroinformatics, Theoretical Biology, and [3]International Graduate School of Neuroscience, Ruhr-University; Departments of [4]Radiology and [5]Pain Management, BG-Kliniken Bergmannsheil, Bochum, Germany.

Received Jul 12, 2004, and in revised form Oct 20. Accepted for publication Dec 1, 2004.

Published online Feb 24, 2005, in Wiley InterScience (www.interscience.wiley.com). DOI: 10.1002/ana.20394

Address correspondence to Dr Tegenthoff, Department of Neurology, Ruhr-University Bochum, BG-Kliniken Bergmannsheil, Buerkle-de-la-Camp-Platz 1, D-44789 Bochum, Germany.
E-mail: martin.tegenthoff@ruhr-uni-bochum.de

© 2005 American Neurological Association
Published by Wiley-Liss, Inc., through Wiley Subscription Services

BOLD signals during strictly nonpainful electrical stimulation applied with 2Hz were received for each IF in separate sessions. Data were analyzed using the Statistical Parametric Mapping software package 99 (Wellcome Department of Cognitive Neurology, London, UK).[11]

As a marker of peripheral tactile acuity, two-point discrimination thresholds on the tip of the IFs were assessed using the method of constant stimuli. One single needle and seven pairs of needles (separated by a distance of 1.0, 1.4, 1.8, 2.2, 2.6, 3.2, and 4mm) were tested in randomized order. After each presentation, the patient had to report the sensation of one or two needles by answering immediately "one" or "two." Each distance was presented seven times resulting in 56 single decisions. The summed responses were plotted against distance as a psychometric function for absolute threshold and were fitted by a binary logistic regression (SPSS; SPSS, Chicago, IL). Threshold was taken from the fit at the distance at which 50% correct responses were reached.[12]

Results

Behavioral treatment over 1 to 6 months led to a persistent decrease in pain intensity (NRS scores: first measurement: 5 ± 2.9 [mean ± standard deviation]; second measurement: 1.2 ± 1.4; Wilcoxon signed rank test: $Z = -1.9$, $p = 0.04$), which was accompanied by a restoration of the impaired tactile discrimination (CRPS normalized to healthy side: first measurement: 65 ± 18.7%; second measurement: 88 ± 7.8%; $Z = -2.2$, $p = 0.02$) and a regain of BOLD contrast in contralateral SI (first measurement: 9 ± 12.4%; second measurement: 66 ± 52.2%; $Z = -2.2$, $p = 0.02$) and SII (first measurement: 13 ± 24.2%; second measurement: 40 ± 36%; $Z = -2$, $p = 0.04$, Kendall τ-b correlation between SI and SII changes: $r = 0.86$, $p = 0.01$, n = 6; Fig). To assess the influence of an in-

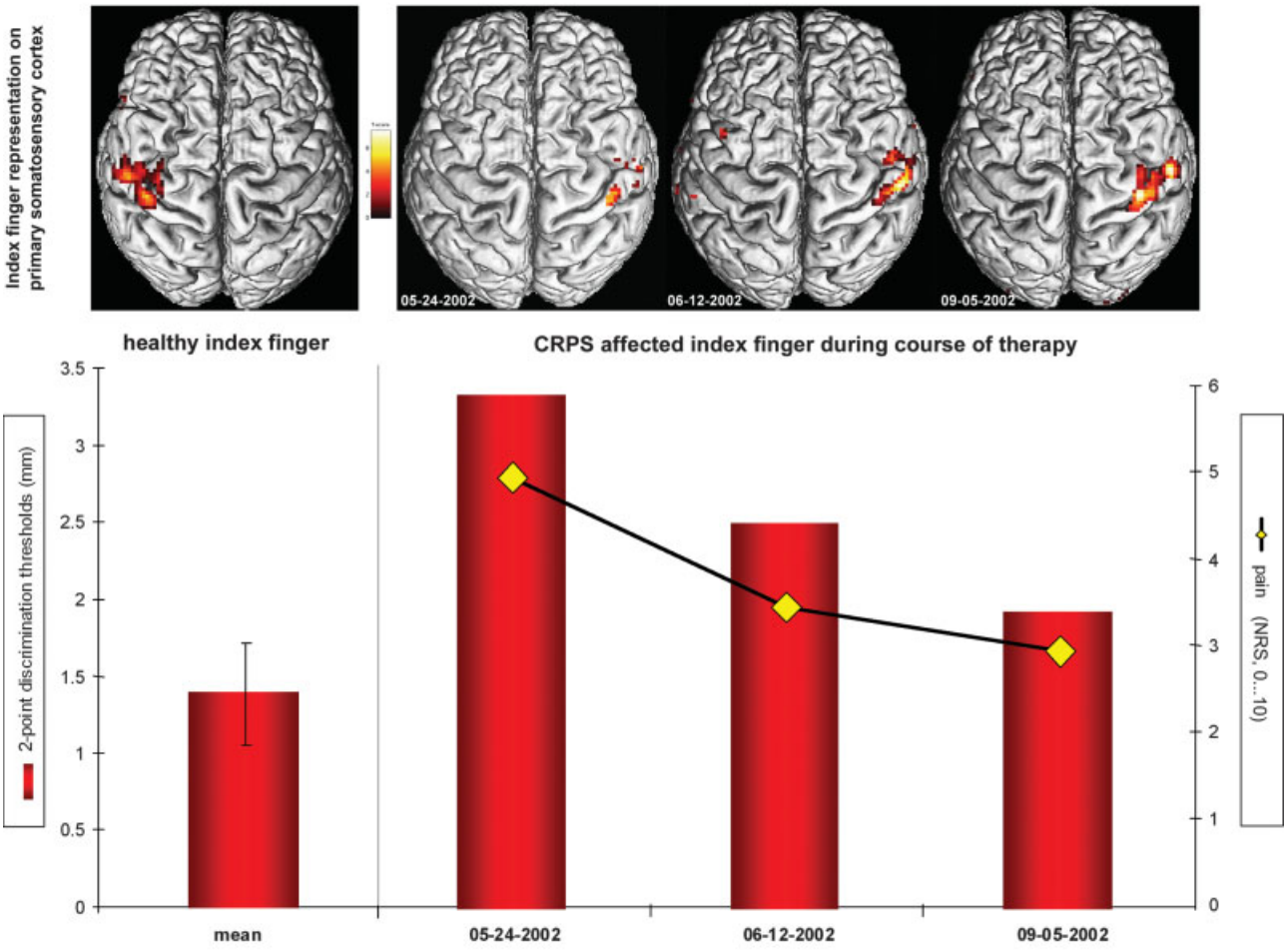

Fig. Changes in primary somatosensory cortex (SI) representation, pain intensity, and discrimination ability during course of therapy. BOLD contrast received from cortical maps on postcentral gyrus (SI) contralateral to the healthy (left image) and to the complex regional pain syndrome (CRPS) affected side (right: images of three consecutive measurements). SPM contrast maps are shown from above projected on the individual rendered T1-weighted magnetic resonance imaging data set. The diagram below shows two-point discrimination thresholds of both sides (left: healthy index finger [IF], red column: mean value, whiskers: standard deviation; right columns: CRPS affected IF) and intensity of CRPS pain (yellow rhombus, three consecutive evaluations). Corresponding clinical parameters and data of cortical maps on SII are listed in Table 2 (Patient 1).

creased motor practice on discrimination performance and cortical maps, we performed a motor task of P0 (Table 1) of the healthy hand during each therapy session. However, we found no changes of spatial discrimination performance (first measurement: 2.1 ± 0.3mm; second measurement: 2.1 ± 0.3mm; $Z = -0.1$, $p = 0.9$) and cortical representations of the healthy IF ($Z = -1.1$, $p = 0.2$ [SI]; $Z = -0.1$, $p = 0.9$ [SII]). Before therapy, we found a significant correlation between two-point discrimination thresholds and mean sustained pain levels indicating that patients with most severe pain showed greatest impairment of tactile discrimination ($r = -0.78$, $p = 0.01$). However, we found no correlation between tactile discrimination and mean degree of immobility (pre: $r = -0.27$, $p = 0.44$; post: $r = 0.2$, $p = 0.57$).

Discussion

Here, we show that cortical reorganization, sensory impairment, and pain in CRPS I is reversible after graded sensorimotor retuning. The repetitive application of graded desensitization, motor tasks, or the combination of both might be considered to explain the observed effects. To assess the influence of an increased motor

Table 1. Four Levels of Sensorimotor Protocols for the Treatment of CRPS Pain

Level of Therapy	p0	p1	p2	p3
Including criterion	No pain under adequate strain	Pain only during movement	Pain less or equal than 5 on the NRS	Pain stronger than 5 on the NRS
Aim	Reestablishment of proprioceptive abilities	Reducing the tactile induced pain training motor functions	Reducing the tactile induced pain	Pain reduction
	Loosening up exercises of contractible joints	Reestablishment of proprioceptive abilities	Moving toward a functional position of the hand	
	Exercises with resistance			
	Increasing fine-motor abilities and strength			
Sensory tasks	Continuation of secondary desensitization (see p1)	Secondary desensitization	Primary desensitization	Soft cushioning
		Harder paint brushes	Immersing the hand in substances which are perceived as comfortable, soft paint brushes	Bandaging
		Household brushes	Cotton wool	
		Hedgehog balls	Soft fabrics	
		Immersion in materials perceived as uncomfortable	Application of warmth or coolness	
		Identification of surface structures without visual assistance		
		Identification of forms without visual assistance		
		Stereognosy exercises Coordination exercises		
Motor tasks	Exercises using increasing amounts of resistance	Grasping/taking hold of bigger structures initially		Immobilization
	Training of differentiated fine-motor abilities	ADL (eg, cutlery with thickened hilts/grips, getting dressed, body hygiene)		
	Achieving independence/more independence in carrying out ADL (see p1)	Swinging movements and writing exercises		
	Testing how much strain the hand can bear, using arts and crafts techniques	Making use of appropriate arts and crafts techniques		
		Exercises featuring the use of light resistance		
Splint	Weaning the hand off the splint	Splint is to be worn only occasionally	Correction of splint's position toward a functional position	Fixing the hand in a pain-free position by means of a splint

Patients were assigned to each level according to their current pain intensity (p = pain adapted level of therapy). The nonaffected hand underwent motor task of p0 during each therapy session.
CRPS = complex regional pain syndrome; NRS = numeric rating scale; ADL = activities of daily living.

Table 2. Clinical Parameters and BOLD Contrast Received from Cortical Maps of SI and SII during Course of Therapy

		Clinical Parameters						BOLD Contrast in SI (CRPS normalized to healthy side)			BOLD Contrast in SII (CRPS normalized to healthy side)		
Patient	Height Threshold (T=)	Affected Upper Limb	CRPS (mo)	Inciting Noxious Event	Current Pain Levels (NRS)	Two-Point Discrimination Performance (CRPS normalized to healthy side)	Degree of Immobility (CRPS normalized to healthy side)	Cluster Level of SI Activity, k_E	MNI Coordinates (*x, y, z* in mm) of SI pattern	Voxel Level, T-Score, SI Activity	Cluster Level of SII Activity, k_E	MNI Coordinates (*x, y, z* in mm) of SII Pattern	Voxel Level, T-Score, SII Activity
1	4.96	Left	12	Radial fracture	5	42	5	4	44, −34, 64	55	18	46, −18, 16	87
			13		3.5	78	20	16	54, −28, 48	79	33	38, −16, 12	88
			16		3	139	5	68	56, −20, 59	97	52	36, −20, 14	129
2	6.83	Right	4	Radial fracture	3	76	10	0	—	0	0	—	0
			5		0.5	81	10	5	−56, −10, 48	86	0	—	0
3	3.37	Left	5	Metacarpus fracture	4	66	50	19	54, −4, 44	78	0	—	0
			7		1	87	50	103	52, −8, 44	232	33	58, −32, 30	115
4	5.12	Left	52	bite wound, phlegmon	4	88	35	30	36, −8, 66	91	0	—	0
			58		2.5	88	15	40	38, −8, 64	103	48	42, −18, 18	87
5	3.13	Left	1	Upper arm fracture	8	77	10	0	—	0	60	50, −26, 26	99
			3		0	93	25	123	54, −6, 38	108	106	52, −28, 20	62
6	4.37	Right	36	Incised wound	8	43	0	4	−50, −2, 42	36	2	−46, −20, 24	28
			37		0	100	100	112	−54, 2, 42	49	23	−48, −24, 20	35

Two-point discrimination thresholds, degree of immobility, cluster level, and T-scores were shown in percentages (CRPS normalized to healthy side). The data of the third measurement in Patient 1 after 3 months of ongoing therapy were not included in statistical analysis.
BOLD = blood oxygen level dependent; SI = primary somatosensory cortex; SII = secondary somatosensory cortex; CRPS = complex regional pain syndrome; NRS = numeric rating scale; MNI = Montreal Neurological Institute.

practice on perceptual and cortical changes, we also had patients exercise the nonaffected side during each therapy session. However, we found no changes of two-point discrimination thresholds, and cortical representations of the nonaffected IF as a possible indicator that repetitive practice of motor tasks alone did not affect peripheral tactile acuity or cortical representation. This absence of perceptual and cortical changes for the healthy IF also indicates the lack of unspecific side effects under ongoing drug therapy.

Results of correlation analyses moreover suggest that, before therapy, mean sustained pain but not impaired mobility seems to be linked to peripheral sensory impairment. If this impairment of tactile perception and pain intensity were, in turn, correlated to changes in BOLD area size or intensity remains speculative because at least one patient showed a lack of cortical responses in the first or second measurement, and correlation analyses therefore missed sufficient explanatory power. Interestingly, this lack of regional activity occurred whenever patients experienced maximum pain. Thus, these findings seem to support the hypothesis that the degree of reduction in somatosensory representation in CRPS I appeared to be linked to pain intensity.[6,7]

Previously, changes in somatosensory maps of amputees were demonstrated to correlate with the intensity of phantom limb pain.[13,14] Different approaches of behavioral treatment that reversed cortical reorganization, for example, sensory discrimination training[15] or myoelectric prostheses,[16] were thereby associated with a decrease in pain. In contrast with amputees, CRPS I occurs without apparent peripheral nerve lesion. Thus, our findings suggest that pain, cortical reorganization, and sensory impairment seem to be reversible also in the absence of any deafferentation of peripheral nerves.

The marked decrease in pain induced by graded sensorimotor treatment protocols and the parallel restoration of cortical maps of SI and SII may offer a new promising treatment direction. The mechanisms mediating the beneficial effects may involve sequential activation of areas in the brain that subserve the affected limb.[17] The presented therapeutic regimen improved discrimination performance as indicated by diminished two-point discrimination thresholds. This together with the increasing reinforcement of motor function might strengthen sensory and proprioceptive feedback mechanisms that, in turn, compete with nociceptive inputs and interact with relays of pain processing and cortical maps in contralateral SI and SII.

This research was supported by the Bundesministerium für Bildung und Forschung (Network "Neuropathic Pain" BMBF, 01EM0102).

We thank Mr. Steve Langan for his skillful editing of this manuscript.

References

1. Stanton-Hicks M, Jänig W, Hassenbusch S, et al. Reflex sympathetic dystrophy: changing concepts and taxonomy. Pain 1995;63:127–133.
2. Bruehl S, Harden RN, Galer BS, et al. External validation of IASP diagnostic criteria for complex regional pain syndrome and proposed research diagnostic criteria. International Association for the Study of Pain. Pain 1999;81:147–154.

3. Juottonen K, Gockel M, Silen T, et al. Altered central sensorimotor processing in patients with complex regional pain syndrome. Pain 2002;98:315–323.
4. Jänig W, Baron R. Complex regional pain syndrome is a disease of the central nervous system. Clin Auton Res 2002;12:150–164.
5. Jänig W, Baron R. Complex regional pain syndrome: mystery explained? Lancet Neurol 2003;2:687–697.
6. Maihöfner C, Handwerker HO, Neundörfer B, Birklein F. Patterns of cortical reorganization in complex regional pain syndrome. Neurology 2003;61:1707–1715.
7. Pleger B, Tegenthoff M, Schwenkreis P, et al. Mean sustained pain levels are linked to hemispherical side-to-side differences of primary somatosensory cortex in the complex regional pain syndrome I. Exp Brain Res 2004;155:115–119.
8. Schwenkreis P, Janssen F, Rommel O, et al. Bilateral motor cortex disinhibition in complex regional pain syndrome (CRPS) type I of the hand. Neurology 2003;61:515–519.
9. Tecchio F, Padua L, Aprile I, Rossini PM. Carpal tunnel syndrome modifies sensory hand cortical somatotopy: a MEG study. Hum Brain Mapp 2002;17:28–36.
10. Allen G, Galer BS, Schwartz L. Epidemiology of complex regional pain syndrome: a retrospective chart review of 134 patients. Pain 1999;80:539–544.
11. Pleger B, Förster A-F, Ragert P, et al. Functional imaging of perceptual learning in human primary and secondary somatosensory cortex. Neuron 2003;40:643–653.
12. Dinse HR, Ragert P, Pleger B, et al. Pharmacological modulation of perceptual learning and associated cortical reorganization. Science 2003;301:91–94.
13. Flor H, Elbert T, Knecht S, et al. Phantom-limb pain as a perceptual correlate of cortical reorganization following arm amputation. Nature 1995;375:482–484.
14. Lotze M, Flor H, Grodd W, et al. Phantom movements and pain. An fMRI study in upper limb amputees. Brain 2001;124:2268–2277.
15. Flor H, Denke C, Schaefer M, Grusser S. Effect of sensory discrimination training on cortical reorganisation and phantom limb pain. Lancet 2001;357:1763–1764.
16. Lotze M, Grodd W, Birbaumer N, et al. Does use of a myoelectric prosthesis prevent cortical reorganization and phantom limb pain? Nat Neurosci 1999;2:501–502.
17. Moseley GL. Graded motor imagery is effective for longstanding complex regional pain syndrome: a randomised controlled trial. Pain 2004;108:192–198.

A Mutant *PSEN1* Causes Dementia with Lewy Bodies and Variant Alzheimer's Disease

Atsushi Ishikawa, MD, PhD,[1,2]
Yue-Shan Piao, MD, PhD,[3] Akinori Miyashita, PhD,[4]
Ryozo Kuwano, MD, PhD,[4] Osamu Onodera, MD, PhD,[5]
Hiroaki Ohtake, MD, PhD,[6] Masahiro Suzuki, MD,[7]
Masatoyo Nishizawa, MD, PhD,[6]
and Hitoshi Takahashi, MD, PhD[3]

We report early-onset parkinsonism and dementia of 18 years' duration in a 52-year-old man whose grandfather and father had suffered from a similar neurological disease. In this patient, we found neuronal loss in various brain regions including the substantia nigra and cerebral cortex, Lewy bodies, cotton wool plaques, corticospinal tract degeneration, cerebral amyloid angiopathy, and a novel three–base pair deletion in exon 12 of the presenilin-1 (PSEN1) gene. We considered that the mutant PSEN1 might play an important role in the pathogenetic process of both aggregation of α-synuclein into Lewy bodies and deposition of β-amyloid into cotton wool plaques.

Ann Neurol 2005;57:429–434

Alzheimer's disease (AD) and dementia with Lewy bodies (DLB) are the two most common neurodegenerative diseases characterized by progressive dementia. In AD, mutations in the presenilin-1 (*PSEN1*)[1,2] and presenilin-2 (*PSEN2*)[3,4] and amyloid precursor protein (*APP*)[5] genes have been identified as causative genetic abnormalities in patients with familial AD. Interestingly, in patients with some mutations of *PSEN1*, occurrence of variant AD with spastic paraparesis (VAD) has been reported.[6–9] It is also known that DLB can occur as an autosomal dominant trait.[10–12] Recently, triplication[13,14] and missense mutation[15] of the

From the [1]Department of Neurology, Nishi-Ojiya National Hospital, Ojiya; [2]Department of Neurology, Brain Disease Center Agano Hospital, Agano; [3]Department of Pathology, [4]Genome Science Branch, Center for Bioresource-Based Researches, [5]Department of Molecular Neuroscience, Resource Branch for Brain Disease, and [6]Department of Neurology, Brain Research Institute, Niigata University, Nijgata; and [7]Department of Neurology, Nagaoka Red Cross Hospital, Nagaoka, Japan.

Received Sep 1, 2004, and in revised form Dec 5. Accepted for publication Dec 6, 2004.

Published online Feb 24, 2005, in Wiley InterScience (www.interscience.wiley.com). DOI: 10.1002/ana.20393

Address correspondence to Dr Ishikawa, Department of Neurology, Brain Disease Center Agano Hospital, 6317-15 Yasuda, Agano 959-2221, Japan. E-mail: ishikawa@agano.or.jp

© 2005 American Neurological Association
Published by Wiley-Liss, Inc., through Wiley Subscription Services