ELSEVIER

NeuroImage

www.elsevier.com/locate/ynimg
NeuroImage 32 (2006) 503 – 510

Patterns of cortical reorganization parallel impaired tactile discrimination and pain intensity in complex regional pain syndrome

Burkhard Pleger,[a,d,*] Patrick Ragert,[a,e] Peter Schwenkreis,[a] Ann-Freya Förster,[b] Claudia Wilimzig,[e] Hubert Dinse,[e] Volkmar Nicolas,[b] Christoph Maier,[c] and Martin Tegenthoff[a]

[a]*Department of Neurology, BG-Kliniken Bergmannsheil, Buerkle-de-la-Camp-Platz 1, 44789 Bochum, Germany*
[b]*Department of Radiology, BG-Kliniken Bergmannsheil, Buerkle-de-la-Camp-Platz 1, 44789 Bochum, Germany*
[c]*Department of Pain Treatment, BG-Kliniken Bergmannsheil, Buerkle-de-la-Camp-Platz 1, 44789 Bochum, Germany*
[d]*University College London, UK*
[e]*Institute for Neuroinformatics, Theoretical Biology, Ruhr-University, 44780 Bochum, Germany*

Received 24 October 2005; revised 22 January 2006; accepted 21 March 2006
Available online 6 June 2006

In the complex regional pain syndrome (CRPS), several theories proposed the existence of pathophysiological mechanisms of central origin. Recent studies highlighted a smaller representation of the CRPS-affected hand on the primary somatosensory cortex (SI) during non-painful stimulation of the affected side. We addressed the question whether reorganizational changes can also be found in the secondary somatosensory cortex (SII). Moreover, we investigated whether cortical changes might be accompanied by perceptual changes within associated skin territories. Seventeen patients with CRPS of one upper limb without the presence of peripheral nerve injuries (type I) were subjected to functional magnetic resonance imaging (fMRI) during electrical stimulation of both index fingers (IFs) in order to assess hemodynamic signals of the IF representation in SI and SII. As a marker of tactile perception, we tested 2-point discrimination thresholds on the tip of both IFs. Cortical signals within SI and SII were significantly reduced contralateral to the CRPS-affected IF as compared to the ipsilateral side and to the representation of age- and sex-matched healthy controls. In parallel, discrimination thresholds of the CRPS-affected IF were significantly higher, giving rise to an impairment of tactile perception within the corresponding skin territory. Mean sustained, but not current pain levels were correlated with the amount of sensory impairment and the reduction in signal strength. We conclude that patterns of cortical reorganization in SI and SII seem to parallel impaired tactile discrimination. Furthermore, the amount of reorganization and tactile impairment appeared to be linked to characteristics of CRPS pain.
© 2006 Elsevier Inc. All rights reserved.

Keywords: Functional magnetic resonance imaging; Complex regional pain syndrome; Tactile perception; Pain; Cortical reorganization

Introduction

The complex regional pain syndrome (CRPS) can occur after a trauma to a limb. Pain as the leading symptom is often disproportional to the initial trauma and therefore subject of interdisciplinary treatment (Baron and Wasner, 2001). According to the classification of the International Association for the Study of Pain (IASP), CRPS is subdivided into two types: type I corresponds to the former reflex sympathetic dystrophy and occurs without an obvious peripheral nerve lesion, whereas type II, formerly called causalgia, refers to cases where a defined peripheral nerve lesion is present (Stanton-Hicks et al., 1995; Bruehl et al., 1999). In both subtypes, the injured extremity is affected without any restriction to single nerve territories and with a predominantly distal manifestation. Autonomic dysfunction (Wasner et al., 1999; Drummond, 2001; Baron et al., 2002), sensory changes (Rommel et al., 2001) and motor impairment (Schwartzman, 1993; Veldman et al., 1993) are known as typical clinical signs, changing with increasing duration and differing individually (Bruehl et al., 2002). Pain that sometimes spreads into distant body regions may be due to an aberrant central pain regulation (Maleki et al., 2000). The neglect-like syndrome (Galer et al., 1995), multifocal dystonia (van Hilten et al., 2001), and hemisensory impairment (Rommel et al., 2001) are discussed as possible indicators of an altered central nervous processing.

Recent experiments using somatosensory-evoked potential (SSEP) mapping or magnetic source imaging during non-painful stimulation of the skin revealed a smaller representation of the CRPS-affected hand on the primary somatosensory cortex (SI) contralateral to the affected side (Juottonen et al., 2002; Maihöfner et al., 2003; Pleger et al., 2004). The amount of this cortical reorganization appeared to be linked to complaints of CRPS pain: low pain was linked to small hemispherical side-to-side differences, while subjects with a distinctive asymmetry reported the highest pain levels (Maihöfner et al., 2003; Pleger et al., 2004).

* Corresponding author. Wellcome Department of Imaging Neuroscience, Institute of Neurology, 12 Queen Square, London WC1N 3BG, UK. Fax: +44 20 7813 1420.
E-mail address: b.pleger@fil.ion.ucl.ac.uk (B. Pleger).
Available online on ScienceDirect (www.sciencedirect.com).

1053-8119/$ - see front matter © 2006 Elsevier Inc. All rights reserved.
doi:10.1016/j.neuroimage.2006.03.045

In the present study, we investigated whether pain-related changes, which only have been reported for SI, can also be found in the secondary somatosensory cortex (SII). Moreover, we questioned whether signal changes in SI or SII might be accompanied by perceptual changes within associated skin territories. To test this hypothesis, we combined functional magnetic resonance imaging (fMRI) during electrical stimulation of the index finger (IF) with assessments of 2-point discrimination thresholds as a marker for tactile perception.

Methods

The study was approved by the Ethics Committee of the Ruhr-University Bochum and was performed in accordance with the 1964 Declaration of Helsinki. Subjects gave their written informed consent. We recruited 17 right-handed patients (10 female, age: 40.1 ± 9.5 years (mean value ± standard deviation), ranging from 22 to 54 years) with spontaneous pain due to CRPS type I of one upper limb without any definable nerve lesion (Stanton-Hicks et al., 1995). All of them fulfilled the revised criteria of the IASP (Bruehl et al., 1999) (Supplementary Table 1). Data from 6 of these patients were also used for one of our recent publications (Pleger et al., 2005). In this earlier study, we showed that graded sensorimotor retuning over 1 to 6 months led to a persistent decrease in pain intensity which was accompanied by a restoration of the impaired tactile discrimination and a regain of cortical signals within the contralateral SI and SII.

Seventeen right-handed subjects (10 female, age: 40.2 ± 10 years, ranging from 23 to 56 years) served as age- and sex-matched controls. To exclude a peripheral nerve injury (CRPS type II), all patients underwent electroneurographic and clinical neurological examination before participation. Patients with cutaneous damages or edema of the CRPS-affected IF were excluded to avoid erroneous high stimulation intensities during fMRI. In all patients, signs of CRPS affected the whole hand and all digits. Clinical MRI measurements (coronal FLAIR, axial T1-w-SE, axial and sagittal T2-w-TSE and diffusion-weighted EPI sequence) were performed to exclude structural abnormalities of the brain. The duration of CRPS was between 1 and 63 months (17.1 ± 20.6 months). Patients estimated their average pain intensity on a Numeric Rating Scale (NRS) ranging from 0 (no pain) to 10 (most extreme pain) with reference to 2 different time windows: firstly, the mean pain intensity experienced during the previous 4 weeks, and secondly, the pain intensity felt directly before fMRI measurement. In addition, they estimated the residual usability of the affected hand (0–100%, see Supplementary Table 2, "clinical parameters"). Patients had not taken central acting drugs for at least 48 h before their participation.

Psychophysical testing

Participants were subjected to an assessment of their spatial 2-point discrimination thresholds using the method of constant stimuli (Dinse et al., 2003). One single needle and 7 pairs of needles (separated by a distance of 1.0, 1.4, 1.8, 2.2, 2.6, 3.2, and 4 mm; each needle with a diameter of 200 μm) were mounted in a circular arrangement on a rotatable disk. The subject's forearm, hand and fingers were placed in a fixed position on a plate above the disk. The plate was moved up and down. The downward movement was stopped at a fixed position above the needles. The IF was held in a hollow containing a small hole through which the finger touched the needles at approximately the same indentations in each downward movement. After each presentation, the patient had to report the sensation of one or two needles by answering immediately "one" or "two". We tested each distance 7 times in randomized order (56 trials per session) over 15 min. The summed responses were plotted against distance as a psychometric function for absolute threshold and were fitted by a binary logistic regression (SPSS©, SPSS Inc.). Threshold was taken from the fit at the distance where 50% correct responses was reached. To assess side-to-side differences in 2-point discrimination thresholds (CRPS-affected vs. non-affected side, right vs. left side of controls), we used the Student's paired *t* test. Group differences (patients vs. controls) were calculated using the 2-sample *t* test. Therefore, CRPS patients and healthy controls were matched for side of dysfunction.

Linear correlation analysis (Pearson) was utilized to test for significant correlation coefficients between 2-point discrimination thresholds, residual usability, current and mean sustained pain levels, and duration of CRPS.

fMRI measurement

fMRI measurement was performed with a whole body 1.5 T scanner (Magnetom Symphony, Siemens Medical Systems, Germany). During fMRI scanning, patient's head was placed in a standard imaging head coil. We acquired blood-oxygen-level-dependent (BOLD)-sensitive images with a single-shot SpinEcho-EPI sequence (TR 1600 ms, TE 60 ms, matrix 64 * 64, field of view (FOV) 224 mm, 5-mm slice thickness, 1 mm gap between slices, voxel 3.5 * 3.5 * 5 mm). Sixteen transaxial slices which covered the whole brain excluding the cerebellum were adjusted according to the AC–PC connection. Each fMRI session consisted of nine blocks of rest and eight blocks of stimulation, each of which contained forty scans (64 s per block). BOLD signal during electrical stimulation of the CRPS-affected and the healthy IF was evaluated in separate sessions. Participants were instructed to keep their eyes closed and to concentrate strictly on the stimulation. The sessions were measured subsequently. To control for a possible shift in attention across sessions, we randomly counterbalanced the session sequence (CRPS side/healthy side) across patients and controls (right side/left side). The same fMRI protocol has been used in recent studies (Pleger et al., 2003, 2005). Anatomical scans were acquired using an isotropic T1-3dGE (MPRAGE) sequence (TI 1100 ms, TR 1790 ms, TE 3.87 ms, matrix 256 * 256, FOV 256 mm, flip angle 15°, 1-mm slice thickness, no gap, voxel size: 1 * 1 * 1 mm) with 160 sagittal orientated slices covering the whole brain.

Stimulation protocol

Electrical IF stimulation was performed during fMRI measurement using a constant-current TENS stimulator (Medicommerz, Kirchzarten, Germany) with conventional ring electrodes (medco) mounted on the tip of the IF. Pulse duration was set to 0.1 ms and the repetition rate to 3 Hz. Stimulation intensity was calibrated to 2.5 times above sensory threshold. The stimulation was well tolerated and did not induce pain.

Data analysis

fMRI data were analyzed using the Statistical Parametric Mapping (SPM) software package, version 99 (Wellcome Depart-

ment of Imaging Neuroscience, London, UK, http://www.fil.ion.ucl.ac.uk/spm). To guarantee a sufficient steady state of BOLD contrast, we discarded the first 10 images of each fMRI session (690 images) from further analysis. The remaining 680 images were realigned, and a mean image in this process was created. After realignment, images were re-sliced using Sinc interpolation. To establish an inter-individual comparability, we used the standard template of the Montreal Neurological Institute (MNI) (voxel size: 2 mm^3) during normalization procedure (Geyer et al., 2000). Afterwards, images were smoothed with a 6-mm (full-width half-maximum) isotropic, three-dimensional Gaussian filter. Statistical maps were estimated with a high-pass cut-off at 256 s and a hemodynamic response function (hrf-lowpass-filter). The mean image which was created during the realignment procedure was finally co-registered to the anatomic volume data set (T1-3dGE sequence scan) to assess topographic arrangement of BOLD signals. For side-to-side comparability, CRPS patients and healthy controls were matched for side of dysfunction.

Regions of interest (ROI) for SI and SII were defined based on the structural mean image of each group (MRIcro software package developed by Chris Roden, Version 1.37, build 4; http://www.mricro.com). The radius of each ROI was set to 12 mm (2* fwhm smoothing filter). In the present study, we had a strong a priori hypothesis. We investigated whether pain-related changes can be found in SI and SII. Thus, random effect analysis (2nd level) was limited to predefined ROIs instead of the whole brain. The main effects maps for either side of the patients (CRPS side/healthy side) were assessed using the one-sample t test ($P = 0.05$; corrected for multiple comparisons). Since the cortical representations of both IFs were assessed in separate sessions, we used the paired t test to assess side-to-side differences. We also compared each side (session) to the corresponding side (session) of the age- and gender-matched control subjects using the 2-sample t test ($P = 0.05$; corrected for multiple comparisons).

To assess a possible relationship between cortical and clinical data (2-point discrimination thresholds, residual usability of the affected limb, pain intensity, duration of CRPS), we conducted SPM correlation analyses on a subject-by-subject level. For each correlation analysis, 2-point discrimination thresholds, residual usability, current and mean sustained pain levels (NRS scores) were used as covariates ($P = 0.05$, corrected for multiple comparisons).

Results

Two-point discrimination thresholds

Two-point discrimination thresholds of the CRPS-affected IF (3.23 ± 0.71 mm (mean ± SD)) were significantly higher than of the contralateral non-affected IF (2.2 ± 0.46 mm, $P < 0.001$) and the corresponding IF of healthy controls (right IF: 1.97 ± 0.39 mm, $P < 0.001$; left IF: 1.98 mm ± 0.35 mm, $P < 0.001$, Fig. 1). We found no differences between the non-affected IF and the corresponding IF of healthy controls (right IF: $P = 0.13$; left IF: $P = 0.12$, Fig. 1).

Linear correlation analysis (Pearson)

Two-point discrimination thresholds were positively correlated with the mean sustained pain levels ($r = 0.71$, $P = 0.001$, Fig. 2c) but not with the current pain level ($r = 0.349$, $P = 0.169$) nor with the residual usability of the affected hand ($r = -0.36$, $P = 0.151$).

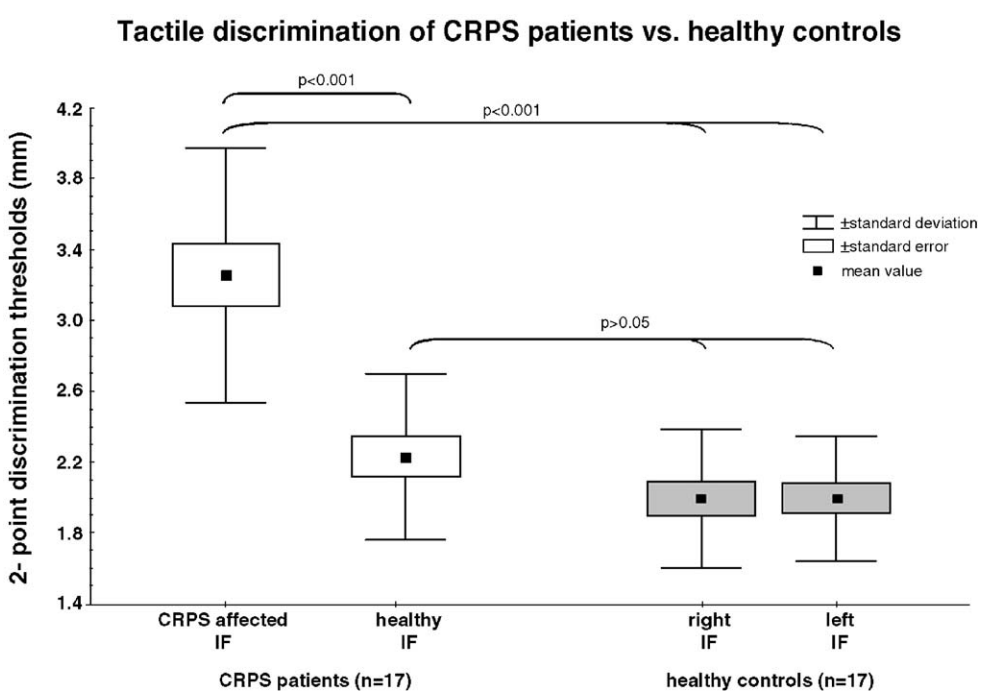

Fig. 1. Side-to-side differences in 2-point discrimination thresholds of CRPS patients vs. healthy controls. The thresholds of the CRPS-affected IF were significantly higher than of the contralateral non-affected IF (white boxes) and the matched sides of healthy controls (grey boxes). Contrarily, we found no differences between the non-affected IF and both IFs of healthy controls (right IF: $P = 0.13$; left IF: $P = 0.12$). Dots represent mean thresholds, boxes show the standard errors and whiskers correspond to the standard deviation.

fMRI measurements

Stimulation thresholds and intensities did not differ between patients (threshold: 1.73 ± 0.56 mA (mean ± SD), intensity: 4.24 ± 1.36 mA) and controls (threshold: 1.67 ± 0.61 mA, intensity: 4.16 ± 1.58 mA; 2-sample t test $P > 0.05$).

Side differences: comparing both hemispheres of CRPS patients, we found a significant higher activation within SI and SII contralateral to the healthy IF (Figs. 3 and 4a). No activated clusters were found for the ipsilateral SII (Fig. 4a, for individual data see Supplementary Table 2) or by comparing both hemispheres of the healthy control subjects.

Group differences: we used the 2-sample t test to compare cortical representations of patients and control subjects. BOLD signals within SI and SII representations contralateral to the matched side of control subjects were found to be significantly higher than the representation contralateral to the CRPS-affected IF (Fig. 4b). The comparison between the healthy IF of CRPS patients and the corresponding IF of control subjects however failed to show any activated clusters (Fig. 4c).

SPM correlation analyses

The SPM correlation analyses revealed significant activation by correlating individual contrast files of the CRPS-affected IF with the mean sustained pain intensity (SI: $r = -0.69$; SII: $r = -0.76$, Fig. 2a) and the 2-point discrimination thresholds (SI: $r = -0.77$; SII: $r = -0.82$, Fig. 2b). Hence, low pain levels were associated with small side-to-side differences, while patients with a distinctive hemispherical and discriminative asymmetry reported the highest pain levels.

Discussion

In the present study, we investigated cortical responses elicited by non-painful stimulations of the skin in CRPS. We found that hemodynamic responses from the cortical representation of the CRPS-affected hand were significantly reduced. In line with recent studies, this may suggest a shrinkage of the extension of the cortical representation for the CRPS-affected side (Juottonen et al., 2002; Maihöfner et al., 2003; Pleger et al., 2004). This was true not only for SI but also for SII. The amount of signal reduction was linked to an impairment of tactile discrimination within corresponding skin regions and to the individual pain intensity. Cortical representation of the unaffected side did not differ from the matched side of control subjects, giving rise to a strict unilateral occurrence of cortical changes in the somatosensory cortices.

Various human imaging studies showed activation not only of SI, but also of SII during the application of painful stimuli (Disbrow et al., 1998; Oshiro et al., 1998; Coghill et al., 1999; Valeriani et al., 2000; Ploner et al., 2002). But only few studies can be found aiming to investigate the functional role of these cortical regions in pain perception. A prominent and highly modulating role in the sensory aspects of pain, including localization of pain and discrimination of its intensity, has been suggested (Bushnell et

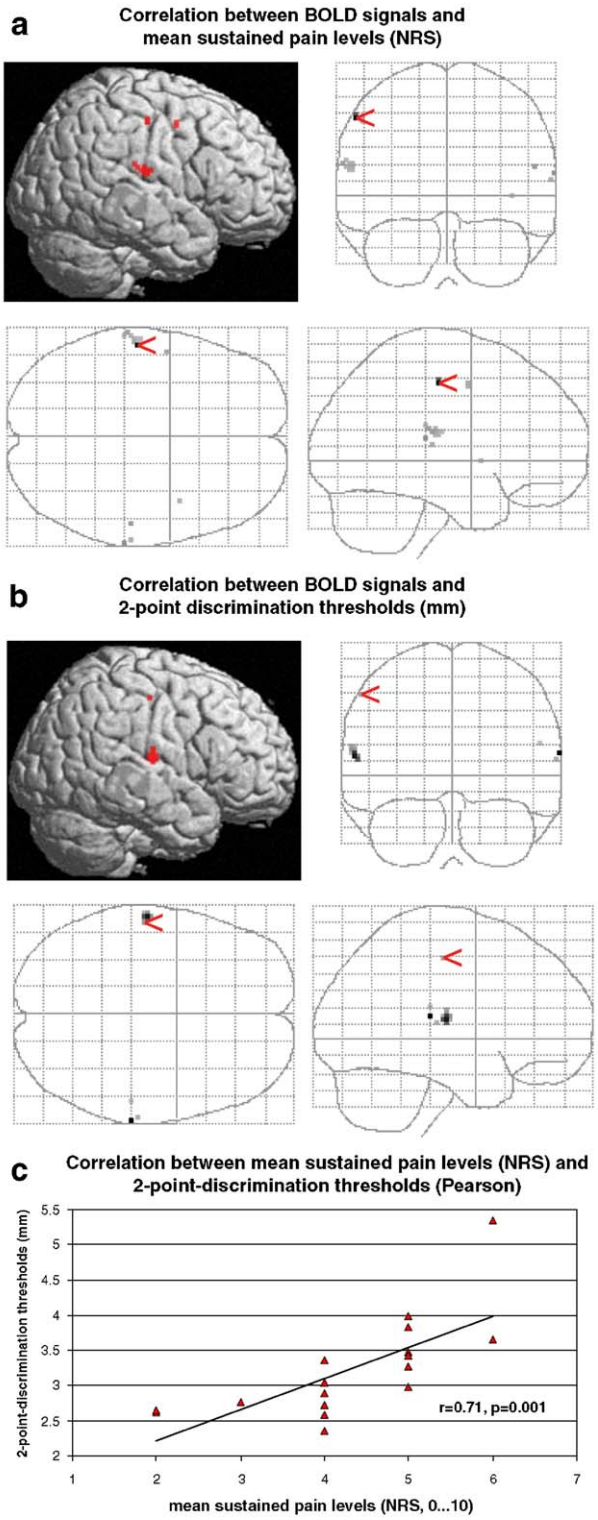

Fig. 2. Correlation analysis. BOLD contrast negatively correlated to (a) mean sustained pain levels and (b) 2-point discrimination thresholds. Pain-related BOLD contrast was found in Brodmann area (BA) 1 (a), whereas perception-related BOLD contrast was found in BA 2 (b) of postcentral gyrus (a: cluster level = 9 v(oxels); t score = 5.3; −50, −26, 54 (x, y, z, mm); b: cluster level = 2 v; t score = 4.8; −58, −18, 48 (x, y, z, mm). Both analyses revealed BOLD contrast localized in the same region of the SII (a) cluster level = 23 v; t score = 4.6; −46, −20, 14 (x, y, z, mm), (b) cluster level = 19 v; t score = 5.7; −46, −20, 24 (x, y, z, mm). (c): Two-point discrimination thresholds were significant correlation with the mean sustained pain levels ($r = 0.71$, $P = 0.001$).

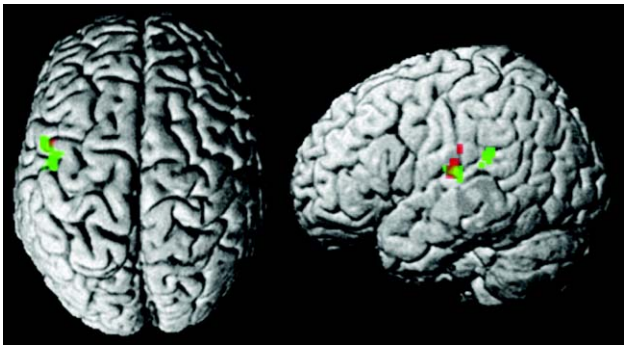

Fig. 3. CRPS (red) and healthy side (green). Significant activation within SI (left picture) and SII (right picture) is projected on a rendered T1-weighted MRI image. SI signal changes are shown in the top view (CRPS: cluster level = 3 v(oxels); t score = 4.3; −57, −7, 45 (x, y, z, mm); healthy: cluster level = 34 v; t score = 4.84; −48, −6,54 (x, y, z, mm)), whereas SII signal changes are shown in side view (CRPS: cluster level = 23 v; t score = 5.3; −44, −18, 16 (x, y, z, mm); healthy: 1st cluster: level = 7 v; t score = 4.48; −60, −38, 24 (x, y, z, mm); 2nd cluster: level = 11 v; t score = 4.91; −54, −20, 14 (x, y, z, mm)).

al., 1999; Peyron et al., 2000). Thus, SI and SII seem be commonly involved in processes that evaluate the nature and localization of the noxious event in order to provide guidance for self-protection mechanisms (Bingel et al., 2003). Beside these studies suggesting a similar functional role of both areas, evidence for their close interconnectedness arises mainly from lesion experiments in animals. Although 25% of the inputs to SII originate from the thalamus (Rowe et al., 1996), ablations of SI in marmosets were found to render somatotopically equivalent parts of SII. This suggests that the activation level of SII depends on either direct or indirect inputs from SI (Garraghty et al., 1990). Based on these findings emphasizing strict top–down mechanisms that rule SII activation, we assume that the signal decrease in SII arises from a reduced forward propagation of inputs generated in corresponding SI maps. Altered thalamic activity and a reduced thalamocortical exchange of inputs may also represent a possible source for SII signal changes.

Beside the investigation of cortical reorganization per se, we addressed the question for their functional relevance. Tactile sensory abnormalities, such as tactile hypoesthesia, hyperalgesia and mechanical allodynia, are frequently present in patients with chronic pain (Nathan, 1960; Lindblom and Verrillo, 1979). A growing body of evidence indicates that dysesthetic phenomena can at least in part be explained by central nervous reorganization (Rommel et al., 1999; Baumgärtner et al., 2002; Finnerup et al., 2003; Giesecke et al., 2004). Moriwaki et al. proposed that the association between pain and tactile hypoesthesia is characterized by a particular topography that may be related to the receptive field organization (Moriwaki and Yuge, 1999). Our findings are in line with these assumptions as we found a close relationship between the amount of tactile impairment, the intensity of CRPS pain and signal changes in associated cortical regions.

On the search for neuronal correlates of CRPS pain, Juottonen et al. already assessed the current pain intensity briefly before the acquisition of head scans. But the scores did not correlate with the amount of SI reorganization (Juottonen et al., 2002). Our findings corroborate these observations. However, patients with CRPS characteristically show a distinctive day-by-day variation in pain intensity. Assuming that measures of ongoing nociceptive inputs may represent a more appropriate score to predict cortical and perceptual changes, we also asked for the mean pain intensity experienced over several foregoing weeks. Using these scores instead of the current pain intensities, we found a significant

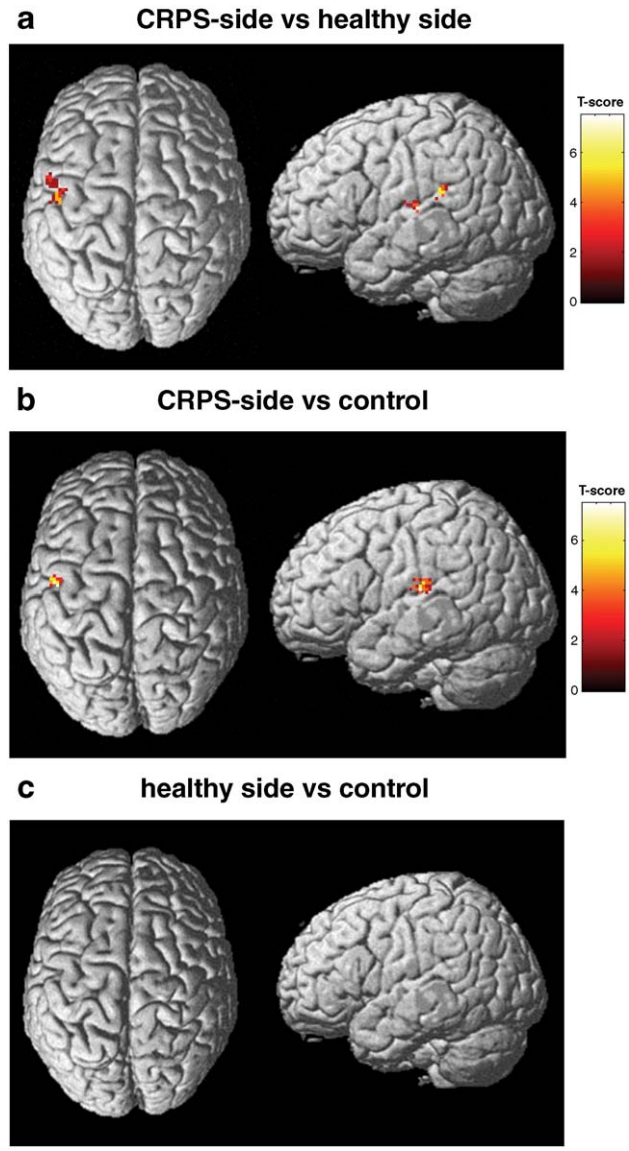

Fig. 4. Hemispherical side-to-side differences. Significant BOLD signal changes (P = 0.05, corrected for multiple comparisons) are projected on a rendered T1-weighted MRI image. SI signal changes are shown in top view (left picture), whereas SII signal changes are shown in side view (right picture). (a) SPM paired t test of both sides of CRPS patients revealed significantly higher BOLD signals within SI (left) and SII (right) contralateral to the healthy IF (S1 parameters: 29 v(oxels); t score = 4.4; −48, −17, 56 (x, y, z, mm), Brodmann area (BA) 3; S2 parameters: 15 v; t score = 4.5; −60, −34, 22 (x, y, z, mm), BA 40; 24 v; t score = 6.1; −60, −38, 22 (x, y, z, mm), BA 40). (b) Representations of the CRPS-affected IF are compared to the matched side of healthy controls. The 2-sample t test revealed significantly higher BOLD signals within SI and SII contralateral to the healthy IF of the control subjects (S1 parameters: 19 v; t score = 6.6; −48, −18, 52 (x, y, z, mm), BA 3; S2 parameters: 84 v; t score = 6.4; −54, −16, 14 (x, y, z, mm), BA 43). (c) Comparing the non-affected side of CRPS patients with the matched side of control subjects by 2-sample t test revealed no signal differences (SI left, SII right).

correlation, not only between pain intensity and the cortical signals, but also between pain intensities and the amount of sensory impairment. In other words, patients with weak signals showed higher tactile thresholds and reported higher pain levels than patients with stronger signal strengths. Only the mean pain intensity appears therefore as a valid predictor for the amount of cortical reorganization in CRPS (Pleger et al., 2004).

A close relationship between ongoing pain and cortical reorganization has not only been observed in CRPS. Previous studies investigating responses to non-painful stimulations revealed similar phenomenon in other chronic pain syndromes. For the carpal tunnel syndrome (CTS), an inverse relation was observed between pain intensity and the extension of SI hand representation. Patients with a small hand extension in SI experienced more pain than patients with a larger hand extension (Tecchio et al., 2002). In amputees with phantom limb pain, several experiments provide evidence that medial shifts of the lower lip representation in SI invaded adjacent cortical regions formally representing the amputated extremity. The pain intensity predicted the amount of invasion as an indirect marker for a diminished cortical SI representation of the amputated limb (Flor et al., 1995; Birbaumer et al., 1997; Lotze et al., 2001). As a basic difference to our study, the diagnosis of CRPS I requires the absence of any peripheral nerve lesion (Stanton-Hicks et al., 1995; Bruehl et al., 1999), whereas complete (amputation) and incomplete (CTS) deafferentiation of peripheral nerves causes changes in associated cortical representations per se (Schwenkreis et al., 2001; Jones et al., 2002). In CTS patients and amputees, the nociceptive inputs may be paralleled by a deafferentiation-induced loss of proprioceptive feedback and the cortical changes may therefore emerge from various, not mutually exclusive, mechanisms. Usually, patients with ongoing pain however try to keep the painful limb in relieving posture. Thus, a loss of proprioceptive inputs may also arise from a pain-dependent immobilization. In the present study, the amount of motor impairment appeared however as a less valid predictor for the reduced cortical signals since we found a lack of correlation between the cortical reorganization and the residual usability of the affected hand.

Regarding the functional organization of the central pain network, recent findings suggest an intense interaction between pain-specific areas and those regions subserving the transmission and processing of both painful and tactile inputs (Clark and Treisman, 2004). Other parts of the pain network appear functionally and anatomically separated (Treede, 2003).

Nociceptors in the skin respond to painful inputs. The activation of these receptors is projected to neurons of the dorsal horn (Morris et al., 2004) via Aδ and C fibers (Djouhri and Lawson, 2004). These neurons serve as a relay between peripheral inputs and ascending pathways transmitting the nociceptive impulses to structures of the brain (Almeida et al., 2004). Among a large number of areas in the brain that respond to nociceptive impulses, the thalamus passes inputs onto SI and SII (Hudson, 2000; Bingel et al., 2004). Tactile stimulation, on the other hand, is perceived by mechanoreceptors (Johnson et al., 2000). The input activates Aβ fibers, and the resulting information is mediated by the dorsal column through the spinal cord to the brainstem, the thalamus, SI and SII (Lynn, 1975; Rowe et al., 1996). Interestingly, in the somatosensory cortex, painful and tactile inputs seem to drive different neuronal populations (Ohara et al., 2004). For SI, recent findings suggest that nociceptive responses are generated in area 1, whereas tactile stimuli activate sources in areas 3b and 1 (Ploner et al., 2000).

Considering possible explanations for the present findings, recent brain mapping experiments in chronic back pain (Flor et al., 1997), fibromyalgia (Montoya et al., 2005), neuropathic pain (Peyron et al., 2004; Hofbauer et al., 2006) and CRPS (Maihöfner et al., 2005) revealed significantly increased activation of the somatosensory cortices during painful stimulation of the affected body region. In the present study, we investigated evoked responses to non-painful tactile stimuli which are assumed to activate different areas within the somatosensory cortex (Ploner et al., 2000; Ohara et al., 2004). In line with recent studies in CTS (Tecchio et al., 2002), amputees (Flor et al., 1995; Birbaumer et al., 1997; Lotze et al., 2001), and CRPS (Maihöfner et al., 2003; Pleger et al., 2004), we found that hemodynamic responses from the cortical representation of the CRPS-affected hand were significantly reduced. Overall, this suggests that ongoing painful inputs in chronic pain syndromes like CRPS lead to an enhanced activation level of those neurons that mainly respond to nociceptive inputs. This, in turn, may initiate a recruitment of processing resources in adjacent regions and cause the observed loss of BOLD signal within cortical regions involved in tactile perception. The parallel tactile hypoesthesia of the affected limb may occur as a consequence of this central reorganization.

Acknowledgments

This work was supported by grants from the Richard Sackler Foundation (C.M. and A.-F.F.) and by the BMBF (NR. 01EM0102). We thank Sonja Sellenmerten for data collection and Steve Langan for his skilful editing of the manuscript.

Appendix A. Supplementary data

Supplementary data associated with this article can be found, in the online version, at doi:10.1016/j.neuroimage.2006.03.045.

References

Almeida, T.F., Roizenblatt, S., Tufik, S., 2004. Afferent pain pathways: a neuroanatomical review. Brain Res. 1000 (1–2), 40–56.

Baron, R., Wasner, G., 2001. Complex regional pain syndromes. Curr. Pain Headache Rep. 5 (2), 114–123.

Baron, R., Schattschneider, J., Binder, A., Siebrecht, D., Wasner, G., 2002. Relation between sympathetic vasoconstrictor activity and pain and hyperalgesia in complex regional pain syndromes: a case–control study. Lancet 359 (9318), 1655–1660.

Baumgärtner, U., Magerl, W., Klein, T., Hopf, H.C., Treede, R.D., 2002. Neurogenic hyperalgesia versus painful hypoalgesia: two distinct mechanisms of neuropathic pain. Pain 96 (1–2), 141–151.

Bingel, U., Quante, M., Knab, R., Bromm, B., Weiller, C., Büchel, C., 2003. Single trial fMRI reveals significant contralateral bias in responses to laser pain within thalamus and somatosensory cortices. NeuroImage 18 (3), 740–748.

Bingel, U., Lorenz, J., Glauche, V., Knab, R., Glascher, J., Weiller, C., Büchel, C., 2004. Somatotopic organization of human somatosensory cortices for pain: a single trial fMRI study. NeuroImage 23 (1), 224–232.

Birbaumer, N., Lutzenberger, W., Montoya, P., Larbig, W., Unertl, K., Topfner, S., Grodd, W., Taub, E., Flor, H., 1997. Effects of regional anesthesia on phantom limb pain are mirrored in changes in cortical reorganization. J. Neurosci. 17 (14), 5503–5508.

Bruehl, S., Harden, R.N., Galer, B.S., Saltz, S., Bertram, M., Backonja, M., Gayles, R., Rudin, N., Bhugra, M.K., Stanton-Hicks, M., 1999. External

validation of IASP diagnostic criteria for complex regional pain syndrome and proposed research diagnostic criteria. International Association for the Study of Pain. Pain 81 (1–2), 147–154.

Bruehl, S., Harden, R.N., Galer, B.S., Saltz, S., Backonja, M., Stanton-Hicks, M., 2002. Complex regional pain syndrome: are there distinct subtypes and sequential stages of the syndrome? Pain 95 (1–2), 119–124.

Bushnell, M.C., Duncan, G.H., Hofbauer, R.K., Ha, B., Chen, J.I., Carrier, B., 1999. Pain perception: is there a role for primary somatosensory cortex? Proc. Natl. Acad. Sci. U. S. A. 96 (14), 7705–7709.

Clark, M.R., Treisman, G.J., 2004. Neurobiology of pain. Adv. Psychosom. Med. 25, 78–88.

Coghill, R.C., Sang, C.N., Maisog, J.M., Iadarola, M.J., 1999. Pain intensity processing within the human brain: a bilateral, distributed mechanism. J. Neurophysiol. 82 (4), 1934–1943.

Dinse, H.R., Ragert, P., Pleger, B., Schwenkreis, P., Tegenthoff, M., 2003. Pharmacological modulation of perceptual learning and associated cortical reorganization. Science 301 (5629), 91–94.

Disbrow, E., Buonocore, M., Antognini, J., Carstens, E., Rowley, H.A., 1998. Somatosensory cortex: a comparison of the response to noxious thermal, mechanical, and electrical stimuli using functional magnetic resonance imaging. Hum. Brain Mapp. 6 (3), 150–159.

Djouhri, L., Lawson, S.N., 2004. Abeta-fiber nociceptive primary afferent neurons: a review of incidence and properties in relation to other afferent A-fiber neurons in mammals. Brain Res. Brain Res. Rev. 46 (2), 131–145.

Drummond, P.D., 2001. Mechanism of complex regional pain syndrome: no longer excessive sympathetic outflow? Lancet 358 (9277), 168–170.

Finnerup, N.B., Johannesen, I.L., Fuglsang-Frederiksen, A., Bach, F.W., Jensen, T.S., 2003. Sensory function in spinal cord injury patients with and without central pain. Brain 126 (Pt. 1), 57–70.

Flor, H., Elbert, T., Knecht, S., Wienbruch, C., Pantev, C., Birbaumer, N., Larbig, W., Taub, E., 1995. Phantom-limb pain as a perceptual correlate of cortical reorganization following arm amputation. Nature 375 (6531), 482–484.

Flor, H., Braun, C., Elbert, T., Birbaumer, N., 1997. Extensive reorganization of primary somatosensory cortex in chronic back pain patients. Neurosci. Lett. 224 (1), 5–8.

Galer, B.S., Butler, S., Jensen, M.P., 1995. Case reports and hypothesis: a neglect-like syndrome may be responsible for the motor disturbance in reflex sympathetic dystrophy (Complex Regional Pain Syndrome-1). J. Pain Symptom. Manage 10 (5), 385–391.

Garraghty, P.E., Pons, T.P., Kaas, J.H., 1990. Ablations of areas 3b (SI proper) and 3a of somatosensory cortex in marmosets deactivate the second and parietal ventral somatosensory areas. Somatosens. Motor Res. 7 (2), 125–135.

Geyer, S., Schormann, T., Mohlberg, H., Zilles, K., 2000. Areas 3a, 3b, and 1 of human primary somatosensory cortex. Part 2. Spatial normalization to standard anatomical space. NeuroImage 11 (6 Pt. 1), 684–696.

Giesecke, J., Reed, B.D., Haefner, H.K., Giesecke, T., Clauw, D.J., Gracely, R.H., 2004. Quantitative sensory testing in vulvodynia patients and increased peripheral pressure pain sensitivity. Obstet. Gynecol. 104 (1), 126–133.

Hofbauer, R.K., Olausson, H.W., Bushnell, M.C., 2006. Thermal and tactile sensory deficits and allodynia in a nerve-injured patient: a multimodal psychophysical and functional magnetic resonance imaging study. Clin. J. Pain 22 (1), 104–108.

Hudson, A.J., 2000. Pain perception and response: central nervous system mechanisms. Can. J. Neurol. Sci. 27 (1), 2–16.

Johnson, K.O., Yoshioka, T., Vega-Bermudez, F., 2000. Tactile functions of mechanoreceptive afferents innervating the hand. J. Clin. Neurophysiol. 17 (6), 539–558.

Jones, E.G., Woods, T.M., Manger, P.R., 2002. Adaptive responses of monkey somatosensory cortex to peripheral and central deafferentation. Neuroscience 111 (4), 775–797.

Juottonen, K., Gockel, M., Silen, T., Hurri, H., Hari, R., Forss, N., 2002. Altered central sensorimotor processing in patients with complex regional pain syndrome. Pain 98 (3), 315–323.

Lindblom, U., Verrillo, R.T., 1979. Sensory functions in chronic neuralgia. J. Neurol., Neurosurg. Psychiatry 42 (5), 422–435.

Lotze, M., Flor, H., Grodd, W., Larbig, W., Birbaumer, N., 2001. Phantom movements and pain. An fMRI study in upper limb amputees. Brain 124 (Pt. 11), 2268–2277.

Lynn, B., 1975. Somatosensory receptors and their CNS connections. Annu. Rev. Physiol. 37, 105–127.

Maihöfner, C., Handwerker, H.O., Neundorfer, B., Birklein, F., 2003. Patterns of cortical reorganization in complex regional pain syndrome. Neurology 61 (12), 1707–1715.

Maihöfner, C., Forster, C., Birklein, F., Neundorfer, B., Handwerker, H.O., 2005. Brain processing during mechanical hyperalgesia in complex regional pain syndrome: a functional MRI study. Pain 114 (1–2), 93–103.

Maleki, J., LeBel, A.A., Bennett, G.J., Schwartzman, R.J., 2000. Patterns of spread in complex regional pain syndrome, type I (reflex sympathetic dystrophy). Pain 88 (3), 259–266.

Montoya, P., Sitges, C., Garcia-Herrera, M., Izquierdo, R., Truyols, M., Blay, N., Collado, D., 2005. Abnormal affective somatosensory brain processing among patients with fibromyalgia. Psychosom. Med. 67 (6), 957–963.

Moriwaki, K., Yuge, O., 1999. Topographical features of cutaneous tactile hypoesthetic and hyperesthetic abnormalities in chronic pain. Pain 81 (1–2), 1–6.

Morris, R., Cheunsuang, O., Stewart, A., Maxwell, D., 2004. Spinal dorsal horn neurone targets for nociceptive primary afferents: do single neurone morphological characteristics suggest how nociceptive information is processed at the spinal level. Brain Res. Brain Res. Rev. 46 (2), 173–190.

Nathan, P.W., 1960. Improvement in cutaneous sensibility associated with relief of pain. J. Neurol., Neurosurg. Psychiatry 23, 202–206.

Ohara, S., Crone, N.E., Weiss, N., Treede, R.D., Lenz, F.A., 2004. Cutaneous painful laser stimuli evoke responses recorded directly from primary somatosensory cortex in awake humans. J. Neurophysiol. 91 (6), 2734–2746.

Oshiro, Y., Fuijita, N., Tanaka, H., Hirabuki, N., Nakamura, H., Yoshiya, I., 1998. Functional mapping of pain-related activation with echo-planar MRI: significance of the SII-insular region. NeuroReport 9 (10), 2285–2289.

Peyron, R., Laurent, B., Garcia-Larrea, L., 2000. Functional imaging of brain responses to pain. A review and meta-analysis. Neurophysiol. Clin. 30 (5), 263–288.

Peyron, R., Schneider, F., Faillenot, I., Convers, P., Barral, F.G., Garcia-Larrea, L., Laurent, B., 2004. An fMRI study of cortical representation of mechanic allodynia in patients with neuropathic pain. Neurology 63 (10), 1838–1846.

Pleger, B., Förster, A.-F., Ragert, P., Dinse, H.R., Schwenkreis, P., Malin, J.P., Nicolas, V., Tegenthoff, M., 2003. Functional imaging of perceptual learning in human primary and secondary somatosensory cortex. Neuron 40, 643–653.

Pleger, B., Tegenthoff, M., Schwenkreis, P., Janssen, F., Ragert, P., Dinse, H.R., Völker, B., Zenz, M., Maier, C., 2004. Mean sustained pain levels are linked to hemispherical side-to-side differences of primary somatosensory cortex in the complex regional pain syndrome I. Exp. Brain Res. 155, 115–119.

Pleger, B., Tegenthoff, M., Ragert, P., Förster, A.-F., Dinse, H.R., Schwenkreis, P., Nicolas, V., Maier, C., 2005. Sensorimotor retuning in complex regional pain syndrome parallels pain reduction. Ann. Neurol. 57, 425–429.

Ploner, M., Schmitz, F., Freund, H.J., Schnitzler, A., 2000. Differential organization of touch and pain in human primary somatosensory cortex. J. Neurophysiol. 83 (3), 1770–1776.

Ploner, M., Gross, J., Timmermann, L., Schnitzler, A., 2002. Cortical representation of first and second pain sensation in humans. Proc. Natl. Acad. Sci. U. S. A. 99 (19), 12444–12448.

Rommel, O., Gehling, M., Dertwinkel, R., Witscher, K., Zenz, M., Malin, J.P., Jänig, W., 1999. Hemisensory impairment in patients with complex regional pain syndrome. Pain 80 (1–2), 95–101.

Rommel, O., Malin, J., Zenz, M., Jänig, W., 2001. Quantitative sensory testing, neurophysiological and psychological examination in patients with complex regional pain syndrome and hemisensory deficits. Pain 93 (3), 279–293.

Rowe, M.J., Turman, A.B., Murray, G.M., Zhang, H.Q., 1996. Parallel organization of somatosensory cortical areas I and II for tactile processing. Clin. Exp. Pharmacol. Physiol. 23 (10–11), 931–938.

Schwartzman, R.J., 1993. Reflex sympathetic dystrophy. Curr. Opin. Neurol. Neurosurg. 6 (4), 531–536.

Schwenkreis, P., Witscher, K., Janssen, F., Pleger, B., Dertwinkel, R., Zenz, M., Malin, J.P., Tegenthoff, M., 2001. Assessment of reorganization in the sensorimotor cortex after upper limb amputation. Clin. Neurophysiol. 112 (4), 627–635.

Stanton-Hicks, M., Jänig, W., Hassenbusch, S., Haddox, J.D., Boas, R., Wilson, P., 1995. Reflex sympathetic dystrophy: changing concepts and taxonomy. Pain 63 (1), 127–133.

Tecchio, F., Padua, L., Aprile, I., Rossini, P.M., 2002. Carpal tunnel syndrome modifies sensory hand cortical somatotopy: a MEG study. Hum. Brain Mapp. 17 (1), 28–36.

Treede, R.D., 2003. Neurophysiological studies of pain pathways in peripheral and central nervous system disorders. J. Neurol. 250 (10), 1152–1161.

Valeriani, M., Le Pera, D., Niddam, D., Arendt-Nielsen, L., Chen, A.C., 2000. Dipolar source modeling of somatosensory evoked potentials to painful and nonpainful median nerve stimulation. Muscle Nerve 23 (8), 1194–1203.

van Hilten, J.J., van de Beek, W.J., Vein, A.A., van Dijk, J.G., Middelkoop, H.A., 2001. Clinical aspects of multifocal or generalized tonic dystonia in reflex sympathetic dystrophy. Neurology 56 (12), 1762–1765.

Veldman, P.H., Reynen, H.M., Arntz, I.E., Goris, R.J., 1993. Signs and symptoms of reflex sympathetic dystrophy: prospective study of 829 patients. Lancet 342 (8878), 1012–1016.

Wasner, G., Heckmann, K., Maier, C., Baron, R., 1999. Vascular abnormalities in acute reflex sympathetic dystrophy (CRPS I): complete inhibition of sympathetic nerve activity with recovery. Arch. Neurol. 56 (5), 613–620.